GANGLION CYSTS

Other names: Bible Cyst, Mucus Cyst *ICD9 727.41*

Definition:
A benign outppouching of the synovial fluid producing layer of a joint.

Anatomy:
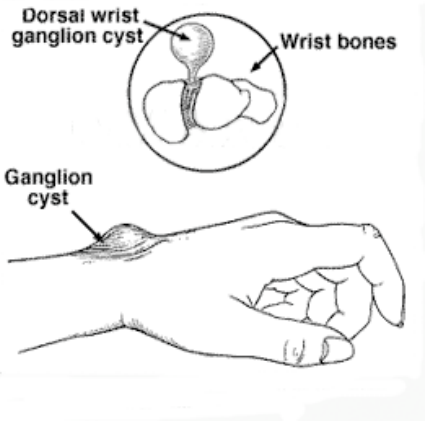

All joints in the body have a dense fibrous sac surrounding the two bone ends that come together. There are layers to this capsule, the inner most one is the synovial layer and this layer secrets the joint fluid that lubricates the joint. The capsule may develop a weakness in the outer dense fibrous layer and the inner layer may "burp" out through this weakness. The cyst is this inner layer that now has extruded through the outer layer. There is a stalk that connects the cyst with the joint it arose from. During the process of coming through the fibrous layer the cyst may be quite painful when the fibrous layer is compressed or stretched (flexing or extending the joint). Cysts can become large and cosmetically problematic. The most common location is the back of the wrist and the second is on the palm side of the wrist towards the thumb side. These cysts can arise from any joint or even the synovial sheath that the tendons run through. Occasionally, arthritis may cause increased joint fluid production that predisposes you to a ganglion cyst.

Affected Persons:
Equally common in Men and Women. Peak incidence in late teens through late twenties.

Symptoms:
Initial symptoms are pain with joint motion. Occasionally the cyst will appear without any symptoms other then a bump under the skin. The bump may feel remarkably firm and is often confused for a protruding piece of bone.

Diagnosis:
Your history is important, however a detailed examination of the affected area is usually diagnostic. Shining a light through the cyst can determine if it is filled with fluid or is solid. Your physician may order Xrays to assess the bone anatomy in the area that the cyst arises from.

Treatment:
Most ganglion cysts are not painful and the decision for treatment is entirely up to the patient. It is possible to drain a ganglion cyst however just as your skin seals it self from the needle used to drain the cyst the cyst wall also heals and re-fills due to the stalk that communicates with the joint. The recurrence rate from drainage (also called aspiration) is over 50%. Recurrnces may occur from a few days to 9-12 months.

Outpatient surgery under a local or regional anesthetic has an advantage in that it can eliminate the stalk that connects the Ganglionn with the joint. The recurrence rate is under 2% at one year with surgical treatment.

Copyright James G. Reid, MD 2003